

# *Sequential SPECT Imaging/Hyperbaric Oxygenation in Long-Term Neurologic Deficits*

*R. A. Neubauer, MD, Medical Director, Ocean Hyperbaric Center, USA  
4001 Ocean Drive, Suite #105, Lauderdale-by-the-Sea, FL 33308  
Tel: (954) 771-4000, Fax: (954) 776-0670*

## Purpose

The purpose of this paper is to describe the varying degrees of recovery that may result from late hyperbaric oxygen intervention in long-term neurological disabilities.

## Summary

In a previous paper it was noted that \$40 billion a year is lost annually with stroke patients. After three months, the patient is usually told by the neurologist that this is the maximum of rehabilitation that can be obtained. Physical therapy, occupational therapy, and speech are plateaued and the patient is either cared for at home or in a nursing home. The same scenario exists for long-term vegetative state, traumatic brain injury, and anoxic ischemic encephalopathy.

Severe brain injury may be likened to an atom bomb; there is an epicenter of irreparable damage, but fanning out from the periphery is the possibility of viability.' With SPECT scanning and hyperbaric oxygenation intervention, a recoverable zone, which can be dormant for periods up to twelve years,<sup>2</sup> can be identified and still be recoverable and capable of firing electrically.

In many patients long-term, ultimate outcome relates to the size and location of the epicenter of irreparable damage, but also the volume and location of the surrounding possible recoverable cells.<sup>3</sup> It must be noted that during the time of hyperbaric therapy, all modalities of physical therapy, occupational therapy, neurofeedback, nutritional counseling, and acupuncture, etc., must be utilized. These cells have been dormant for a number of years and have lost their myoneural pathways.

## Materials and Methods

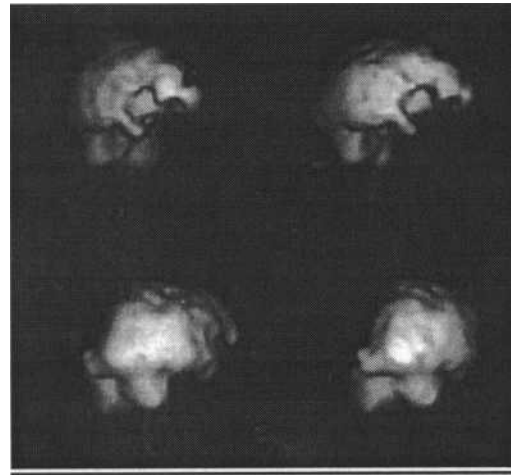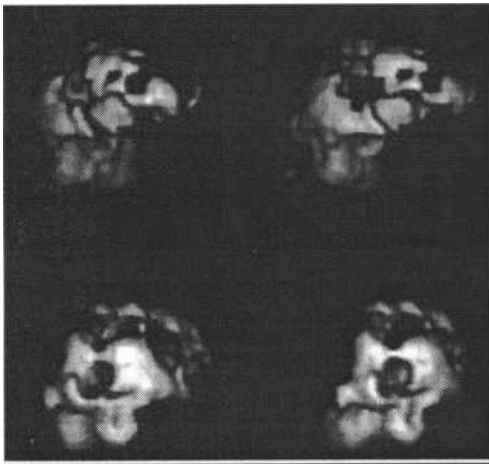
The Ocean Hyperbaric Center specializes in the treatment of cases in which all other modalities have been tried and results have been unsatisfactory. Our Center accepts patients from around the world. Most of the cases seen at the Center are semi-comatose or comatose with classical coma scales ranging from 3-10.

On each patient, a single photon emission computerized tomography scan was performed on an Elscint single-headed gamma camera. The patients were also videotaped. Review of previous medical records was accomplished and the patient was begun on a course of hyperbaric oxygenation treatments. A physical examination was done, especially a minimal neurological examination. The patient was followed clinically by the attending physician, therapists, and the family. Usually after approximately forty treatments, a

second scan was performed. In certain cases because of logistics, the second scan was done after twenty treatments of hyperbaric oxygenation. All patients were treated at 1.5 ATA, for one hour - twice a day in a Vickers monoplace chamber compressed with 100% oxygen. Seizure disorder was not a contraindication, and the patients under those conditions were treated at 1.1 - 1.25 ATA. The number of treatments ranged from eighty to six hundred. All modalities of physical therapy, occupational therapy, speech, neurofeedback, nutritional counseling, and occasionally, acupuncture, were employed as part of the multi-disciplinary approach to resurrect the dormant, idling neuron.

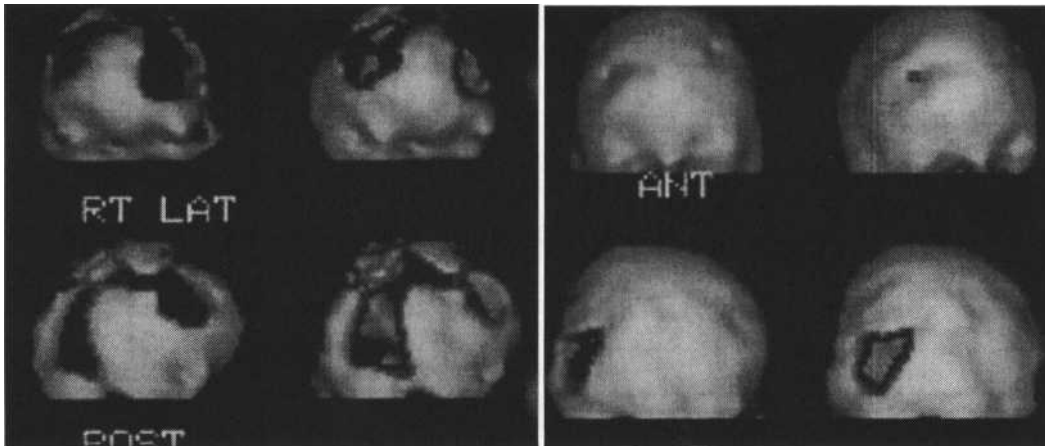
### Case Reports

#### LAS



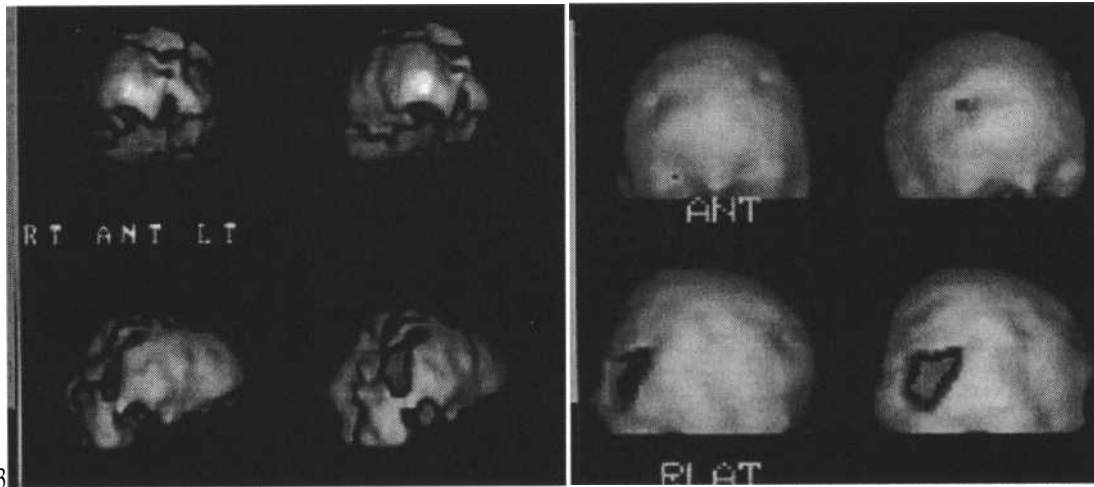
Eighty-nine year old woman who had a severe left mid-cerebral occlusion which has left her hemiplegic, bedridden, aphasic, confused, and has a PEG tube. She was seen having made minimal improvement to where she was wheelchair bound and occasionally on a walker, but continues with marked hemiplegia. The family was told nothing further could be done. She was seen six months later at the Ocean Hyperbaric Center and began a course of hyperbaric oxygenation treatments. SPECT scans revealed a severe deficit, but a substantial improvement occurred around the edge with treatment. The patient then became ambulatory, was able to feed herself, her bowels became normal, became self-sufficient and really had no neurologic deficit with the exception of speech deficits. Over the years the patient has had 171 hyperbaric oxygenation treatments. The major improvement occurred after 118 treatments in a sequential nature.

## 2. MC



Patient is a 23 year old male who had a near-death hanging as the result of an attempted suicide on March 30th, 1989.. The patient was packed in ice and hospitalized for two months. He had a tracheotomy and G-tube and was at a rehab facility for four months. He has been at home for 8.5 years. In 1995, because of problems with the G-tube, half of his stomach was removed. When seen, the patient was a Glasgow Coma Scale of 3 with marked spasticity (typical coma spasticity of all extremities. His eyes were rolled back and he was non-verbal and non-communicative. He received 53 treatments of hyperbaric oxygenation at 1.5 ATA , one hour each. The improvements were increased awareness and reduction of spasticity in the arms and wrists. Tracking with the eye. He was much more relaxed, vocal, alert. The family was pleased. He had 150 hyperbaric oxygenation treatments and the changes were dramatic. The patient was able to communicate. The tracheotomy and G-tube were removed and the bowels became normal. The patient was semi-ambulatory with a walker and much of his intelligence has returned. Although the patient has not returned fully into society yet, there has been a reduction in care. The improvements of the patient, 8.5 years after the incident, have been rewarding.

### 3. GS



A twelve year old female patient who received 91 hyperbaric oxygenation treatments along with physical therapy, occupational therapy, and speech. The results were impressive and cognitively she became much brighter, and more alert and aware of her surroundings. The spastic diplegia disappeared and she was able to ambulate. The PEG tube was removed, the coldness of the feet disappeared, the patient was able to sleep well; the fatigue disappeared, and the patient regained considerable fine motor control.

4. The most unusual case treated at the Ocean Hyperbaric Center was that of a thirty-one year old white male who had attempted suicide with carbon monoxide poisoning twelve years previously. His mother drove him from central Pennsylvania to the Ocean Hyperbaric Center and said "do something". He was comatose; Glasgow Comas Scale of 5. Should the mother have called me regarding a twelve-year coma case, I would not have advised her to bring her son to the Center. However since she had made the trip, we agreed to treat her son. After about forty treatments of hyperbaric oxygenation, there was considerable improvement in the frontal lobe. The patient began to come out of the coma, and was actually more rational than one would expect for carbon monoxide poisoning. He was able to move all of his extremities, able to feed himself, and begin to carry on a conversation. The family was able to find a chamber for home use because of the anticipated 250 to 300 hyperbaric oxygenation treatments required for maximum recovery. After 250 hyperbaric oxygenation treatments, much to everyone's amazement, this patient entered back into society with no cognitive or physiological defects; a rare case.

#### Discussion

After insurance for therapeutic modalities have expired, many patients are basically designated to the wastebasket; that is, the family is told by the physician that nothing further can be done and the patient should be taken home and kept comfortable if possible. If funds are available, the patient is placed into a nursing home. In many

instances, it is suggested at the time of the acute insult that a do not resuscitate order is desirable.

A life plan for a typical patient treated at the Ocean Hyperbaric Center is explained. This was for a fifteen year old male in a vegetative state from traumatic brain injury three years previously. He had a PEG tube and tracheotomy. The life plan was calculated primarily by his attorneys. Considering hospitalization, housing, vans, drugs, attendants, care of the PEG and tracheotomy tubes, physical therapy, occupational therapy, and if with all modern miracles the patient should live to be sixty-five years old, the cost to the family and insurance company for life care was estimated at \$82 million dollars. In similar cases treated at the Ocean Hyperbaric Center, it was possible to remove the PEG tube in nearly all of the patients, and the tracheotomy was discontinued in a large number as well. Very few of the patients re-entered society without neurologic defect. They were however able to communicate - either verbally or with computer, eat normal food, some going from wheelchair to crutches or a quad cane, and the more seriously injured patients were able to get up on a walking brace. The overall improvement of the Glasgow Coma Scale for most of the patients was from a 3 to a 14 - 15 on the scale. Bowels became normal and many were feeding themselves. They had far less hospitalizations, much less drugs, and less attendant needs. The savings to the family for the improvement of the patient was substantial and the savings to the insurance companies were immense.

### Conclusion

When the medical profession says nothing further can be done, in advanced neurological dysfunctions, they may be absolutely right. Under these circumstances, with such thinking, nothing will ever be done. There is, however, a certain group of these patients that have recoverable brain. This may be demonstrated with SPELT or PET scanning as was done in the cases presented. Associated with long-term hyperbaric oxygenation therapy, physical therapy, occupational therapy, speech, nutritional counseling, and occasionally acupuncture and biofeedback, were utilized

All of the above cases treated at the Ocean Hyperbaric Center were those in which no further therapy was advised as they had reached the maximum of neurorehabilitation. Current neurorehabilitation depends primarily upon plasticity; that is, the ability of one part of the brain to take over another. It relies upon the organization and reorganization of the impaired and non-impaired sensory and motor neurons. The degree of asymmetry and the increasing decasation at the cord-medullary junction play a major role. *Adding recoverable brain to this menu, a whole new era of neurorehabilitation will hopefully be realized.*

There are many cases seen at The Ocean Hyperbaric Center where if hyperbaric oxygenation had been instituted at an early stage, many long-term neurologic disabilities would not have occurred. The literature is replete with animal and human study showing

the effects of hyperbaric oxygenation in the acute stroke, the acute traumatic brain injury, and the acute anoxic ischemic encephalopathy which account for such tremendous degrees of disability.<sup>4</sup> It is hoped that this work will stimulate further interest in the field of chronic neurological disabilities and that hyperbaric oxygenation will become an integral part of neurorehabilitation.

## REFERENCES

1. Astrup, Siesjo, and Symon, "Thresholds in Cerebral Ischemia - The Ischemic Penumbra". *Stroke*, 12:723-725, 1981.
2. Neubauer R., Enhancing Idling Neurons. *The Lancet*; March 3, 1990. p 542
3. Neubauer R., James P., Cerebral Oxygenation and the Recoverable Brain. *Neurological Research*, 1998, Vol. 20. Sup. 1, 533-536
4. Jain KK, Toole JF, Hyperacute Hyperbaric Oxygen Therapy for Cerebral Ischemia, Winston-Salem, NC, Nov. 1997