

Hyperbaric Oxygenation for Lyme Vasculitis

W. P. Fife, Ph. D.

R. A. Neubauer, M. D.

Purpose

It is the purpose of this paper to demonstrate the positive effects of hyperbaric oxygenation on severe encephalopathy occurring in Lyme Disease as a synergistic treatment with antibiotics.

Summary

Lyme disease is a tick-borne disease caused by a *Borrelia* spirochete, usually *Borrelia burgdorferi* which was first recognized in late 1975 although a disease resembling Lyme has been recognized in Europe for over 100 years. It is endemic in the northeast United States, but may be found throughout the U.S. The larvae of the tick hatch in the spring and are not infected at birth. However, they become infected from mice or other animal hosts and hibernate throughout winter. They become active as infected nymphs in the summer and as ticks may be carried by any warm blooded animal. In humans, the disease is especially devastating and may even be fatal. In some instances an entire family may become infected. Since the tick is less than 1 mm in diameter, it often is not seen even when the consequences of the infection appear. The mainstay of therapy for this disease is prompt and efficacious antibiotic therapy. It has been noted that the tick cannot live in a hyperoxic environment and a project was begun by Dr. Fife to utilize hyperbaric oxygenation in conjunction with antibiotics in an attempt to eradicate the spirochete.

Introduction

Lyme disease may be difficult to diagnose because seronegative Lyme Borreliosis is not rare and present tests are not completely reliable. In some instances, even while symptoms are present its antigen may be negative, and its antigens can persist in humans after symptoms disappear, even if antibiotics have been used. For this reason it may not be possible to demonstrate the presence or absence of the spirochete at any particular time. This makes any study of treatments difficult to evaluate and quantify. Further, unless the physician is alert to the possible presence of the disease the test may not be ordered, and the disease may not be included in a differential diagnosis which may include flu like symptoms, fatigue, malaise, arthralgias, myalgias, fever, headache, multiple sclerosis, Alzheimer's disease, motor neuron disease and cardiomyopathies or fatality. Of considerable concern is the fact that tissue cultures show that fibroblasts tend to protect the spirochete against antibiotics, and indeed, several eukaryotic cell types provide the Lyme disease spirochete with a protective environment, contributing to its long-term survival, and possibly explaining the reason for the lack of uniform results from any antibiotic so far tried. Even very toxic drugs such as 5-fluorouacil, trimethoprim and sulfamethoxazole have not inhibited the growth of borreliae.

The seriousness of this disease may be seen by a review of the heroic treatment which often is used. Perhaps the most effective therapy is intravenous antibiotics which when

continued for as long as 10 months in some patients still may not destroy the spirochete or relieve the symptoms. (Liegner).

One of the usual initial signs of Lyme infection is painless erythema with a bullseye rash at the site of infection, but the symptoms invariably become exacerbated as the disease develops. There may be abnormalities of the nervous system including cognitive, cardiac myopathies including heart failure, joint and muscle pain, fever, headache, and if not treated may result in inflammatory autoimmune changes of a profoundly crippling nature.

Treatment usually is successful if antibiotics are aggressively initiated early in the course of the disease. However, a large number of victims do not respond to any known antibiotic and become permanent invalids. In fact, in advanced stages there does not appear to be any completely effective treatment.

Records show that there were 11,603 new cases of Lyme disease reported nationwide in 1995, and there were 1,703 new cases reported that year in New Jersey alone. The increase in new cases may be seen by the 10-fold increase in reported cases during the past 10 years; with 15,000 new cases being reported in 1999.

The diagnosis and treatment of this disease is often difficult. Present understanding of the human immune response to *B. Burgdoferi* infection is rudimentary. Firstly, only 2/3 of the patients are seropositive at the initial diagnosis and the serological manifestations are not precise or reliable. For example, the Western Blot, OpsA, or ELISA often are not always positive at the same time. Further, many patients seropositive for several years after all symptoms have disappeared. For this reason, it is not possible at this time to have an objective and reliable way of assessing the effectiveness of any particular treatment. The problem of diagnosis was nicely expressed by Burrascano ¹² who stated, "Lyme remains a clinical diagnosis as no currently available test, no matter the source or type, is definitive in confirming whether an infection with *Borrelia burgdorferi* is present, or if so, whether the infection is active and responsible for the patient's symptoms. The entire clinical picture must be taken into account, including a search for the many subtleties that experienced clinicians have learned to look for. Thus, it is necessary to rely in a major way on the judgment of a physician who has had experience in this disease.

In fact, Liegner has listed "False Teachings" concerning Lyme disease as follows:

1. Patients with late Lyme disease almost invariably are seropositive.
2. 28 days of intravenous antibiotic therapy is virtually always curative: continued symptoms following such treatment means the diagnosis was wrong.
3. Neurological Lyme disease is established by selective intrathecal antibiotic synthesis: In absence one can feel positive that there is no central nervous system infection by *B. burgdorferi*.
4. It is easy to distinguish neurological Lyme disease from multiple sclerosis.

For these reasons it is difficult to provide an objective diagnosis of Lyme disease based on serology alone.

The use of hyperbaric oxygen therapy for the treatment of Lyme disease was discovered by serendipity in our Laboratory, when hyperbaric oxygenation was used to treat a 14 year-old patient who had developed severe crippling inflammatory arthritis as a result of untreated Lyme disease (personal observation). The result of hyperbaric oxygenation treatment was that all pain disappeared after two weeks of hyperbaric oxygenation therapy and the disease appeared to be halted. Since that time, 17 other Lyme disease patients have been treated for from 10 days to 4 weeks to see if this was a valid observation. Again, the symptoms of Lyme disease disappeared, or nearly so in all patients, and all have continued to improve in the weeks following treatment.

Discussion

The rationale for the use of hyperbaric oxygenation in Lyme disease initially was to suppress the autoimmune effects resulting from *B. burgdorferi* that had caused the severe arthritic changes and pain, and which had made the patient a permanent invalid.

This was based on previous studies which showed that it was possible to suppress some aspects of the autoimmune system with hyperbaric oxygenation. One indication of this was that if a homogenate of Freund's Adjuvant and bovine brain was injected subcutaneously into the foot pads or nuchal area of adult rats, within several weeks they developed progressive paralysis resembling multiple sclerosis. This disease, called Experimental Allergic Encephalomyelitis or EAE (considered to be an animal model for multiple sclerosis) resulted in an autoimmune response and death. However, if the adjuvant was injected into immature animals and daily hyperbaric oxygenation treatments immediately begun, the onset of the paralysis did not occur and the animals reached adulthood. If the hyperbaric oxygenation treatments then were discontinued, the disease appeared and was quickly fatal. Suppression of the autoimmune system in humans with hyperbaric oxygenation has been known for a number of years.

Since it appears that fibroblasts can protect the spirochete against antibiotics, the question must be raised as to whether hyperbaric oxygenation would penetrate such tissues and have any direct effect on *B. burgdorferi*. This would appear to be a valid possibility since it is well known that oxygen at an elevated partial pressure effectively saturates all tissues even crossing the blood-brain barrier. The benefit of such penetration would depend upon the sensitivity of the spirochete to elevated levels of oxygen.

The effects of oxygen on this organism was demonstrated by the work of Austin, who showed that in vitro cultures in which the oxygen and carbon dioxide were ambient ($PO_2 = 160$ mm Hg.), there was a loss of infectiveness, while if cultured in 4% O_2 -5% CO_2 , ($PO_2 = 30$ mm Hg.), the infectiveness remained viable. Since under normal conditions the partial pressure of oxygen at the tissue level is only approximately 30 mm Hg, it would appear doubtful if the organism would be suppressed while the host was breathing air. This study suggest that this organism is sensitive to elevated levels of oxygen which are achieved by hyperbaric oxygenation therapy. If the subject breathes pure oxygen at a barometric pressure of 2.36 atmospheres, absolute (ATA), the inspired PO_2 will be 1,794 mm Hg, and the tissue oxygen is approximately 300 mm Hg. This may

explain why hyperbaric oxygenation appears to be effective in the treatment of this disease.

The possible use of increased oxygen in the treatment of Lyme was also suggested by Dr. Burgdorfer himself, and by Schwan.

Materials and Methods

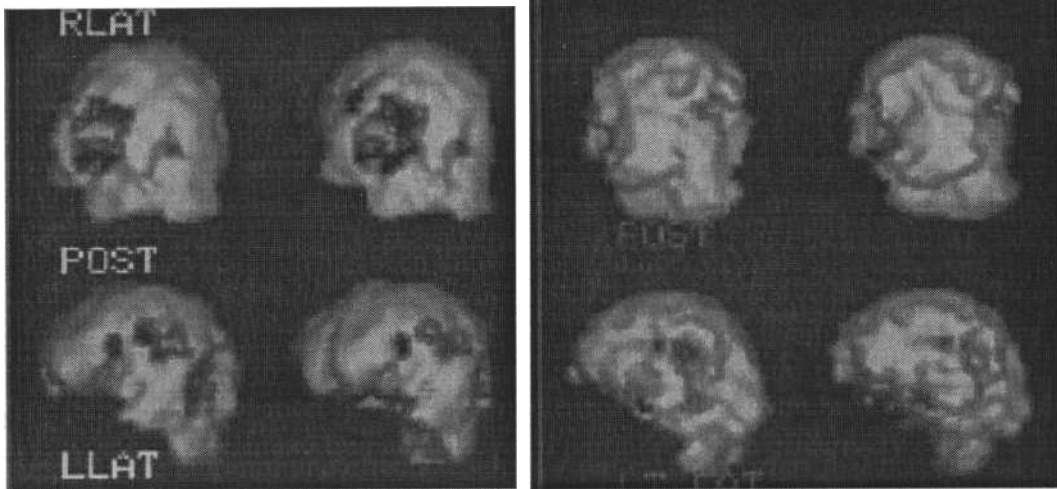
Because of Dr. Fife's astute observation that hyperbaric oxygenation may be an effective treatment and a possible cure for Lyme disease, 91 patients were begun treatment at Texas A&M. Of these, 75 completed the treatment at anywhere between 40 and 120 exposures of hyperbaric oxygenation at 2.36 ATA, 60-90 minutes per day. These patients were all treated in a multiplace chamber with air and oxygen delivery via mask or hood. At the Ocean Hyperbaric Center twelve patients were treated specifically for their cerebral encephalopathy associated with long-standing Lyme disease. Four such cases will be presented. The protocol used was originated by Dr. Fife, 2.4 ATA, one hour twice a day, five days a week for anywhere from 20 to 200 treatments. Each case had a single photon emission computerized (SPECT) scan prior to treatment and repeat scans were followed sequentially at 20, 40, 80, and at the end of the hyperbaric oxygenation treatments. These scans were performed on an Elscint single headed gamma camera. The isotope used was technetium 99, either Ceretec or Neurolite. The hyperbaric chambers are Vickers monoplace compressed with 100% oxygen. In certain instances after a large number of treatments, early oxygen toxicity was noted in several cases and the pressure was reduced to 2.2 ATA.

Results

In the Fife series, 75% completed the series of pressurized oxygen between 10 and 133 treatments. All except 7 of them experienced significant improvement or cessation of symptoms lasting from three months to six years. In the Fife series, 67% of the patients remained on antibiotics during and after hyperbaric oxygenation. At the Ocean Hyperbaric Center one patient, C.Z., had not been on antibiotics for several years and was not started on them during the treating for his encephalopathy. The other patients all remained on continuous antibiotics and were advised not to stop them for a period of at least three months after which time a SPECT brain scan would be performed to see if there was any deterioration. Of the twelve cases treated at the Ocean Hyperbaric Center, four case reports follow.

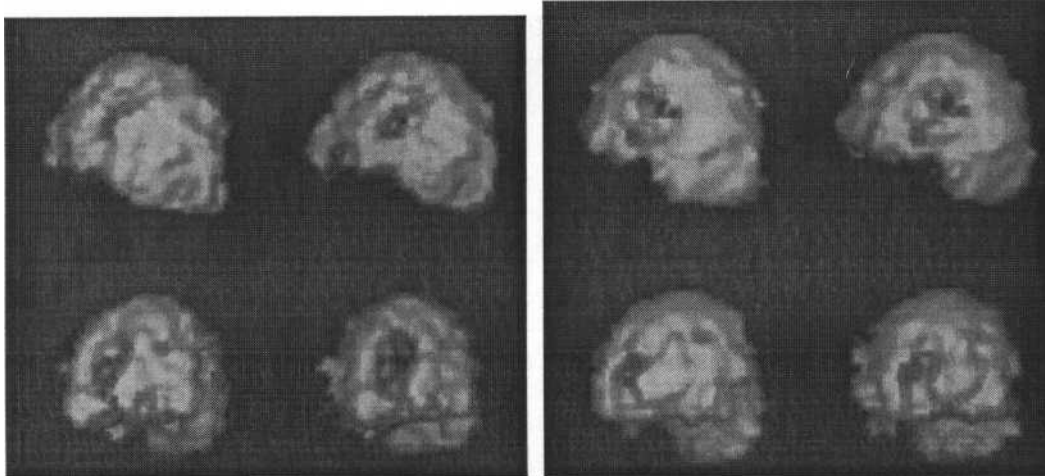
Case Reports

1. C.Z.



Fifty-nine year old white, male professor with Lyme Disease. He remembers being bitten by a tick in 1989, but the diagnosis was not made until 1995. The symptoms have been intermittent and the main problem is that of fatigue, joint aches, and over the past years, short-term memory loss. He also suffers from profuse sweating with the least bit of energy. He has now had 106 hyperbaric oxygenation treatments and states that his energy level is up, his joint pains are less, and that his memory has improved remarkably. He still has the sweating problems and there is still some degree of fatigue, but is not taking antibiotics.

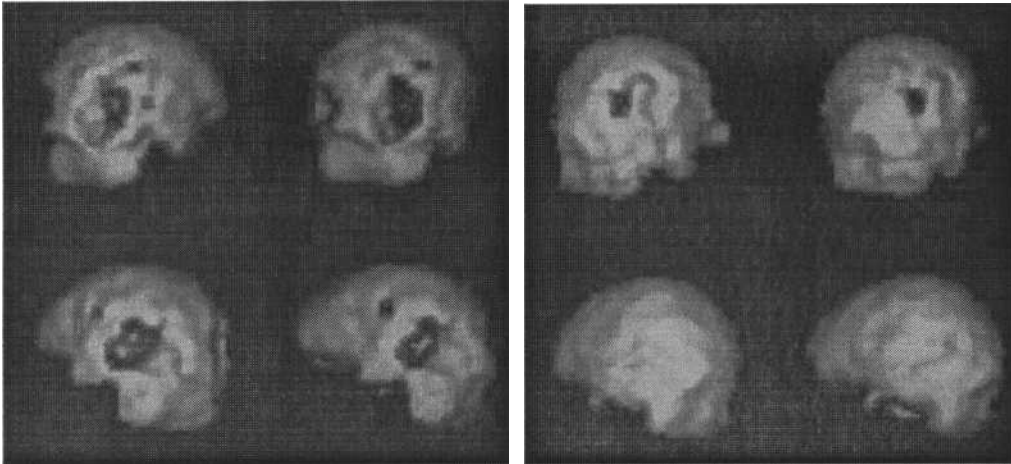
2. M.K.



A fifty-eight year old female who suffered from severe Lyme Disease with marked CNS problems associated with frequent grand mal seizure disorder. She had been tried on virtually all seizure medications but still remained mentally alert and active. Her biggest disappointment was not being able to drive a car. She was seen twelve months after the diagnosis was made at the Ocean Hyperbaric Center. She, however, had been symptomatic and misdiagnosed for 22 years. She was begun on a protocol of 2.4 ATA for 90 minutes, one to two times per day depending upon logistics. Initially the seizure disorder almost virtually disappeared but as the treatments increased in number, it was felt that early oxygen toxicity had ensued and the seizure disorder began to return, but

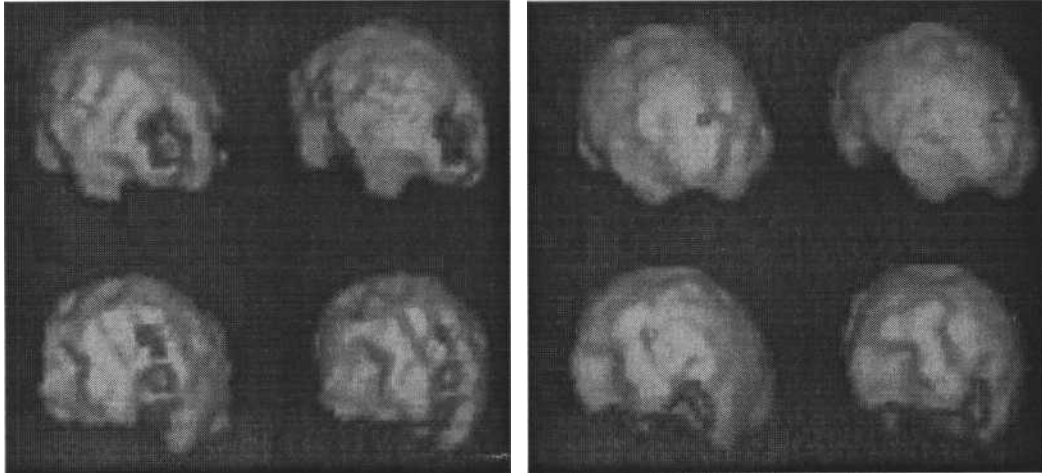
was associated pneumonia requiring hospitalization and different antibiotics. She was followed seriously by neurology. After 25 hyperbaric oxygenation treatments, she was advised by the medical director to discontinue treatment temporarily to see if the seizure disorder could be brought under control with standard drugs. This case illustrates that hyperbaric oxygenation is not a panacea. There was some improvement in the SPECT scan and the actual dose of hyperbaric oxygenation is not really known in Lyme Disease.

3. M.C.:



Forty year old male was diagnosed with Lyme Disease in April of 1997 although symptomatic and undiagnosed for at least twelve months prior. He was a firefighter and became unable to work with severe joint pain, fatigue, and his short-term memory was exceedingly bad. He could read a page or two and not remember anything. He felt "done in and useless". He was begun on a course of hyperbaric oxygenation treatments at 2.4 ATA, for 60-90 minutes, two times per day. He progressed nicely losing the joint aches and pains and fatigue. His memory began to come back to where he was capable of reading an entire volume and remember what was on almost every page. He stated that he had never had an ability to retain things or a memory like this before. Because of continuing improvement clinically and on scans, the patient had a total of 141 hyperbaric oxygenation treatments and felt 100% normal and capable of going back to working as a firefighter full-time. He was advised not to stop the antibiotics abruptly, but to stay in touch with his infectious disease physician and the antibiotics could possibly be discontinued for a period of three months. A repeat SPECT scan should be performed at that time.

4. A. L.



Age 19, remembers that he was bitten by a tick in 1992. Over a period of years when the patient was first treated he developed short-term memory loss, fatigue, headaches, joint pain, depression, and comprehensive problems. On December 22", 1998 a SPECT scan was performed which showed primarily bilateral occipital deficits. After 30 hyperbaric oxygenation treatments his concentration was completely better, his memory was better, his mood was better, and he had considerably less fatigue. The patient did continue the antibiotics while on therapy. The scans showed a substantial filling in of the basic deficits compatible with the clinical improvement.

Conclusion

In the series treated at the Ocean Hyperbaric Center results of SPECT imaging gave documentation that hyperbaric oxygenation was a valid treatment of Lyme Disease. This tended to document the work done by Dr. Fife. Because of the difficulty in actual diagnosis it would be suggested that all patients with possible Lyme Disease should have a SPECT or functional brain imaging. Although these cognitive modes and other anomalies may accompany many other diseases, these changes can also come in Lyme Disease and probably respond to hyperbaric oxygenation irrespective of the cause. The serologic diagnosis is mandatory for Lyme. Although difficult to document the positive effects, the long-term results of Dr. Fife's protocol has established this as a treatment of choice. It was the use of his protocol that resulted in the positive changes in Lyme encephalopathy which paralleled the clinical improvement. Frequently the diagnosis can be made only by an astute physician.

Some subjects discontinued antibiotic therapy during hyperbaric oxygenation treatments while others continued their regular regime of antibiotic therapy, either intravenous or oral. No adverse reactions were anticipated from the administration of pure oxygen at the barometric pressures and exposure times used, except that the Jarisch-Herxheimer reaction was expected to appear in all subjects if destruction of the spirochetes took place. Since the subjects were breathing pure oxygen during most of the time they were in the chamber, no decompression sickness was expected and none did occur with the standard treatment which was used at least 2,000 times each year at Texas A&M. In fact, the body content of nitrogen is decreased during oxygen exposure, thus adding an even greater safety factor against decompression sickness.

At the Ocean Hyperbaric Center it must be noted that pressures of 2.4 ATA for 90 minutes twice a day in certain cases became borderline oxygen toxicity and the pressure was therefore reduced to 2.2 ATA for 90 minutes and then eventually to 2.2 ATA for 60 minutes twice a day. This was represented not by seizure disorder but by periods of fatigue and very transient confusion. This was noted particularly in the cases of M.K. and M.C.

Although further studies are necessary, the possibility exists that since the spirochete is a micro-aerophilic like organism, the use of hyperbaric oxygenation actually may eradicate it, and that with proper treatment duration, and all of the patients may have an ultimate disappearance of positive Lyme symptoms.

Addendum

A question should be raised as to the possibility that Lyme spirochete can be transferred to the fetus if the mother is or becomes infected during pregnancy. Five children so far treated appeared to have been infected in utero. It has been shown that even if the mother is seronegative, the fetus may still present with spirochetes, sometimes with severe consequences. This, in turn raises the possible safety and effectiveness of hyperbaric oxygenation therapy during pregnancy. There are a number of cases in which pregnant patients have required hyperbaric oxygenation for such things as life threatening gas gangrene, or carbon monoxide poisoning. In such cases hyperbaric oxygenation was found not to harm the fetus. It cannot be stated that hyperbaric oxygenation would affect spirochetes in a fetus because of the vasoconstriction of the uterine artery. In animal studies it has been shown that the fetus does not receive the same partial pressure of oxygen as does the mother. This, of course, raises the question as to whether the fetus can be treated effectively with hyperbaric oxygenation. Repeated hyperbaric oxygenation therapy has not been shown to be teratogenic in humans when used in the clinical situation.

SUGGESTED READING

Weber, K., [et. al.](#) Erythema migrans disease and related disorders. *Yale J. Biol Med* 57:13-21, 1984.

Lawrence, C., Lipton, R., Lowy, F., Coyle, P. Seronegative chronic relapsing neuroborreliosis. *Eur Neurol.* 1995; 35: 113-117.

Georgilis, K., Peacocke, M., Klempner, M. fibroblasts protect the Lyme disease spirochete, *Borrelia burgdorferi*, from ceftriaxone in vitro. *J. Infect. Dis* 166 (2): 440-4, 1992.

Fallon, B., Nields, J., Burrascano, J., Leigner, K., BelBene, D., Liebowitz, M. The Neuropsychiatric manifestations of Lyme Borreliosis.

Liegner, K. B. burgdorferi - Seek and ye shall find expanding envelope. J of Spirochetal and Tick-Borne Disease Foundation Vol. 1, No 4 1944.

Morshed, M., Konishi, H., Nishimura, T., Nakazawa, T. Evaluation of agents for use in medium for selective isolation of Lyme disease and relapsing fever Borrelia species. European J. of Clin Microbiol & Infectious Diseases. 12(7): 512-8, 1993

Liegner, K. Lyme disease and the clinical spectrum of antibiotic responsive chronic meningoencephalomyelitis. In: Lyme Disease Foundation Symposium, 1966.

Preac-Mursic, V., Weber, K., Pfister, H1, Wilske, B., Reinhardt, S., Prokop, J. Survival of Borrelia burgdorferi in antibioticly treated patients with Lyme borreliosis. Infection 1989; 17:355-359.

Anon. Lyme Disease 1995. In: Clinical Update in Musculoskeletal Med. J. Musculoskeletal Med. 1996, (8): 45.

Fein, L., Heir, G. Lyme Disease - An Overview. In: The Surveillance of Infectious Diseases. Thacker, Keewhan, Brachman. J. of the AMA 4 March 1983. Vol 294, No 9.

Leigner, K. Lyme Disease: the Sensible Pursuit of Answers. J. Clinical Microbiol Aug. 1993, p. 1961-1963.

Burgdorfer, W., National Institute of Health, Rocky Mountain Lab. Personal letter dated 10 September 1996.

Leigner, K. No standard criteria exists for the interpretation of Western Blot for Lyme Disease. Teterboro Laboratory, Teterboro, NJ. 1995.

Monthly Report, Texas A&M Hyperbaric Lab

Welch, D. Study on rats with Freund's Adjuvant, Texas A&M Hyperbaric Lab. (unpublished).

Ginaldi, L., Pilotti, L., Sacchetti, S., Laurenti, R., Pkzzuto, F., Valdarnii, D. Modification of immune parameters after hyperbaric oxygen treatment in healthy volunteers: preliminary data. J. Hyperbaric Med. 6:1, 19-24, 1991.

Georgilis, K., Peacocke, M., Klempner, M. Fibroblasts protect the Lyme Disease spirochete, Borrelia burgdorferi, from Ceftriaxone in [vitro. J. Infect. Dis. 1992](#); 166:440-4.

Austin, F., Maintenance of infective Borrelia burgdorferi Sh-2-82 in 4% oxygen - 5% carbon dioxide in vitro. Canadian J. Microbiol. 39(12):1103-10, 1993 Dec.

Burrascano, J., Managing Lyme Disease, Diagnostic hints and treatment guidelines for Lyme Borreliosis. Tenth Edition, Feb 1995:Med. Lyme Care Center.

Schwan, T., National Institute of Health Rocky Mountain Lab. Personal Letter 21 August 1996.

Schultzer, S., Coyle, P., Belman, A., Golightly, M., Drulle, J. Sequestration of antibody to *Borrelia burgdorferi* in immune complexes in seronegative Lyme disease. *Lancet* 1990; 335:312-315.

MacDonald, A. Gestational Lyme Borreliosis implications for the fetus. In: *Rheumatic Diseases of Clinics of North America*. 15:4, 658-677. 1989, W.B. Saunders Co.

Fein, L., Heir, G. Lyme Disease - An Overview. In: *The Surveillance of Infectious Diseases*. Thacker, Keewhan, Brachman. J. of the AMA 4 March 1983. Vol 294. No 9.

Warren, J., Sacksteder, M., Thunning, C. Oxygen immunosuppression, modification of experimental allergic encephalomyelitis in rodents. *J. Immunol* 1978; 121:315-320.

Geriatrics, Medicine for Midlife and Beyond, July 2000.

Lymes Disease - An Overview: The Surveillance of Infectious Diseases.

Oxygen immunosuppression, modification of experimental allergic encephalomyelitis in rodents.